

Semi-Automated Analysis of Dynamic 3D Upper Airway MRI

Ahsan Javed, Yoon-Chul Kim, Krishna S. Nayak
Magnetic Resonance Engineering Laboratory

Introduction

Obstructive sleep apnea (OSA) is characterized by airflow cessation during sleep as a result of the collapse of pharyngeal airway [1]. Knowledge of Obstruction sites has been of great interest to researchers because direct inspection of airway may facilitate treatment planning and outcomes (3-5).

The most common approach is 2D mid-sagittal MRI, which provides only partial coverage of the narrowed upper airway and is very sensitive to imperfect localization. Recently, Kim, et. Al have shown that 3D Real time MRI is more desirable for studying OSA since it provides complete coverage of the upper airway.

In order to better visualize the collapse of the upper airway segmentation is needed. Manual segmentation is very time consuming and costly. Here we present a method for semi automated 3d Segmentation of the upper airway using multi seeded region growing.

Experiments

Imaging: Data were acquired on a GE Signa 3T EXCITE HD system (40 mT/m, 150 T/m/s), using a 3DFT gradient echo sequence with a 6 cm excitation slab thickness, flip angle 5, matrix size of 100 x 80 x 40. The scan was continuous for (2min) with FOV= 16 x 12.8 x 6.4 cm³, spatial resolution 1.6 mm³ isotropic, TR= 3.8ms TE = 1.74ms. [6]

Reconstruction: Image reconstruction was base on SPIRiT and was performed in MATLAB (The Math works, South Natick, MA).[6,8]

Evaluation: 3D segmentation was performed to segment the airway from the 3D data sets using multi seeded 3D region growing algorithm in MATLAB(The Math works, South Natick, MA). Seeds were placed in the airway above the soft palate and below the soft palate in the first frame. Semi automated segmentation results for the first frame are verified and new seeds are automatically generated for the subsequent frames to begin the automated segmentation. The seed for every frame is updated based on the previous frame to keep the seed within the region of interest and track the airway in cases of minor movements. The 3D volumes that are generated from segmentation allow us to visualize collapse of the airway and are displayed in figure 2 and figure 3.

Discussion & Future Work

We have demonstrated the potential of multi-seeded 3D region growing segmentation for segmenting the upper airway. Results may be further improved using automated thresholding, and improving the method for generating new seeds for subsequent frames and by removing some bleeding that appears in some of the segmented data sets. Intensity correction followed by de-noising might also help improve the segmentation results.

These volumes also need to be compared to volumes generated from manual segmentation by an expert using Dice coefficients.

References

- [1] Malhotra A. Lancet 237-245, 2002. [2] Carvalho JLA et al. MRM 57:639, 2007. [3] Rama AN et al. Chest 1139:1147, 2002. [4] Isono S et al. Laryngoscope 769-774, 1999. [5] Ng At. et al. Sleep 666-671, 2006. [6] Kim CY et al. MRM, 2013. [7] Kirally, A. Academic radiology, 1153-1168, 2002.[8]Lustig M. et al. MRM 1182-1195, 2007.

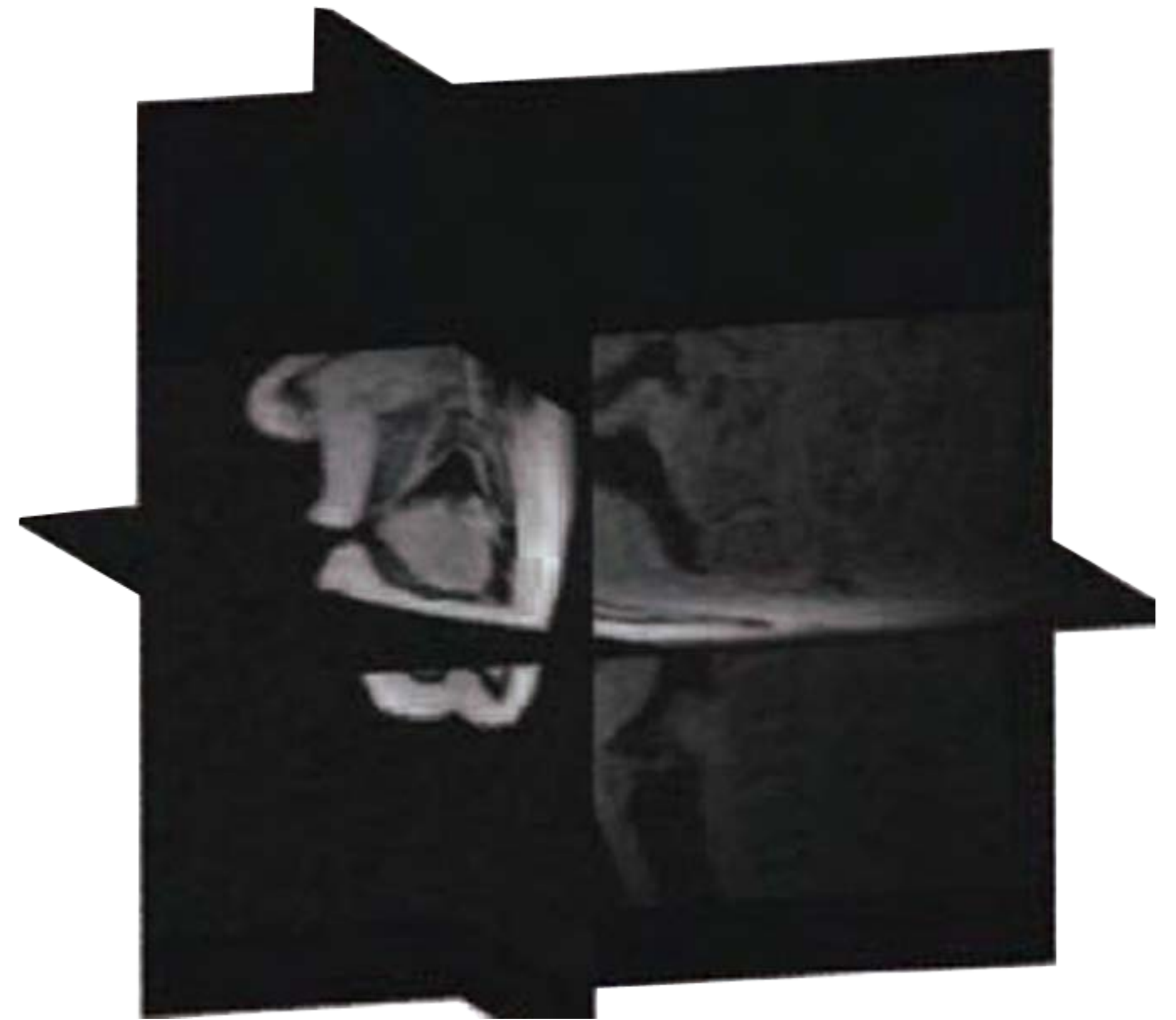


Figure 1: Sagittal, coronal and axial slices of a 3D data sets [6]

Results

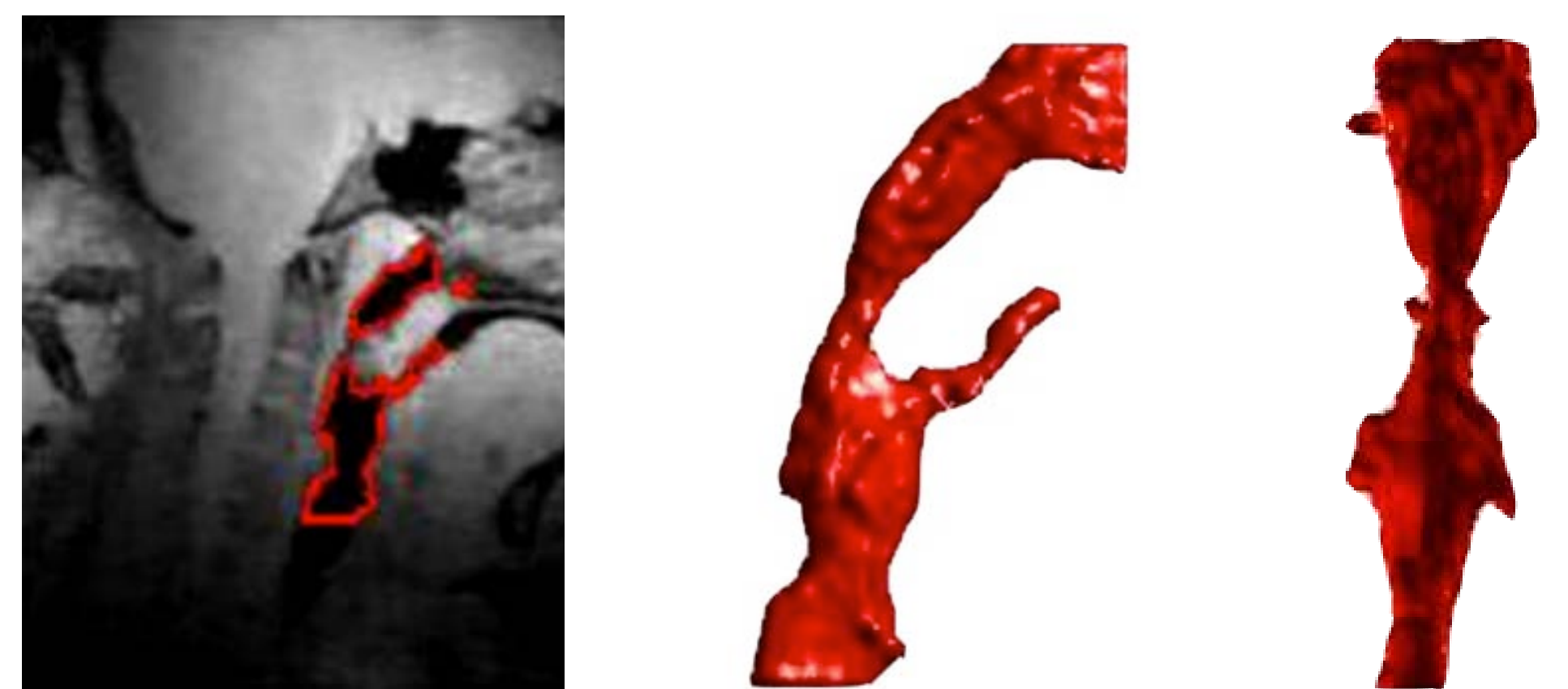


Figure 2: Mid-sagittal slice with segmented contour (Left), sagittal view of segmented upper airway volume (middle), coronal view of segmented upper airway volume (right) during normal breathing (mouth).




Figure 3: Mid-sagittal slice with segmented contour (Left), sagittal view of segmented upper airway volume (middle), coronal view of segmented upper airway volume (right) during occlusion shows airway collapse that results in airflow cessation.